

Patient Name: [REDACTED]
Procedure Date: 11/9/2010
MRN: [REDACTED]
Date of Birth: [REDACTED]
Attending MD: [REDACTED]

Referred by: [REDACTED]

Exam: Colonoscopy

Indications: Screening for colorectal malignant neoplasm, Hematochezia

Medicines: Midazolam 5 mg IV, Fentanyl 100 micrograms IV

Procedure: After I obtained informed consent, the scope was passed under direct vision. Throughout the procedure, the patient's blood pressure, pulse, and oxygen saturations were monitored continuously. Endoscope CFH-180AL- 2600236 was introduced through the anus and advanced to the ileocecal valve. The colonoscopy was performed without difficulty. The patient tolerated the procedure well. The quality of the bowel preparation was good.

Findings: A pedunculated polyp was found at 25 cm proximal to the anus. The polyp was 10 mm in size. This was left in situ.

An infiltrative partially obstructing medium-sized mass was found in the sigmoid colon. The mass was partially circumferential (involving or lumen circumference). The mass measured five cm in length. No bleeding was present. This was biopsied with a cold forceps for histology between 15cm and 20cm. Area was successfully injected with 4 mL India ink for tattooing: just distal to the mass - 2mm each on opposite sides.

The exam was otherwise without abnormality.

Complications: No immediate complications

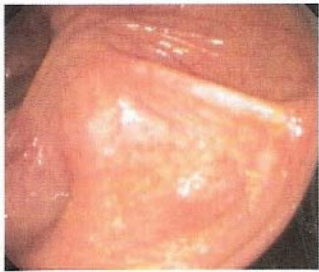Impression:

- One 10 mm polyp at 25 cm proximal to the anus.
- Likely malignant partially obstructing tumor sigmoid colon. Biopsied.
- The examination was otherwise normal.

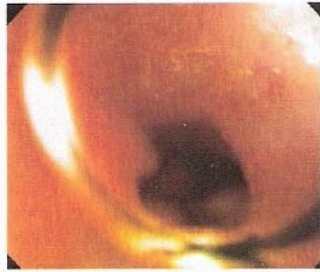
Recommendation:

- Await pathology results.
- Refer to a surgeon.

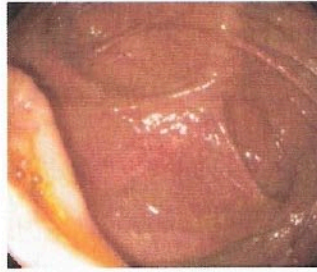
Images:



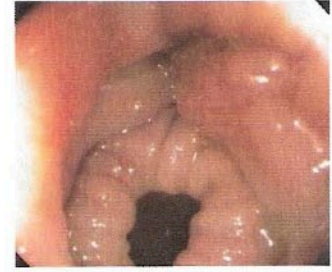1 normal appendiceal orifice



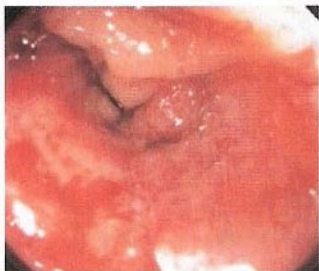
2 normal terminal ileum



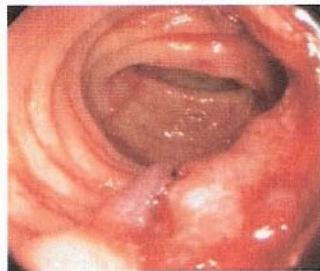
3 normal cecum



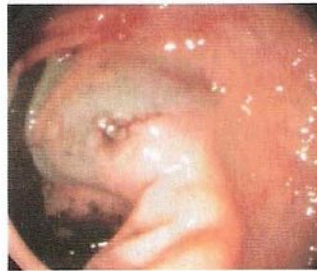4 polyp - 25cm



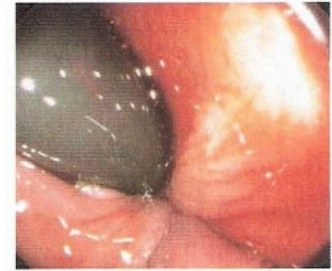
5 mass at 15cm



6 mass at 15cm



7 tattoo at 12cm



8 normal distal rectum

11/9/2010

This report has been signed electronically.

Number of Addenda: 0

Note Initiated On: 11/9/2010